

Piezosurgical lateral approach with Autogenous tooth graft combined with CGF-CD34+matrices – State of the art sinus lift

SALVI Diego², HALIMI (HUDHRA) Estela¹

^{1,2} Aldent University, Faculty of Dental Sciences, Department of Oral Surgery, Tirana–Albania

ABSTRACT

In sinus floor augmentation, different bone grafting materials alone or combined with concentrated growth factors are used. The main goal is to achieve the new bone formation in the atrophic posterior maxilla as a prerequisite for dental implants placement and consequently, to ensure the long term success of implant-supported prosthesis. Reconstruction of the alveolar bone is often a challenge due to the possible adverse events and complications following the procedures. The gold standart of bone grafting materials is Autograft. Tooth-derived bone graft material, which is proved to be rich in bone growth factors and bone morphogenic proteins (BMPs), is becoming a practical substitute to bone grafting. CGF-s are also well known to accelerate the new bone formation. In our case report, we performed a piezosurgical lateral approach with tooth bone graft combined with CGF CD34+ matrice. Based on radiographic controls after 2, 4 and 5 months, very good results in new bone formation were achieved. Also we achieved a pain free and with no complications postoperative period.

THE AIM

To describe a piezosurgical sinus augmentation technique emphasizing the role of autologus tooth graft combined with CGF-CD34+ matrices in guided bone regeneration with reduced morbidity of the patient.

INTRODUCTION

Sinus lift is a reliable technique used to augment and reconstruct the residual alveolar bone in the posterior atrophic maxilla. The crestal and lateral approaches are the most widely performed techniques. The succes rate of sinus augmentation technique is the usage of biomaterials of choice. (1,2,3)

Recently, autogenous tooth bone graft have come to light out the biomedical waste of extracted teeth. Tooth and bone exhibit similar biochemical compositions. Both of them consist, in fact, of 18% collagen, 2% proteins, 70% inorganic portion (hydroxyapatite), and 10% of fluids. Both tooth and alveolar bone are derived from neural crest cells and are made up of the same type I collagen. Despite years of effort the 'perfect' bone reconstruction material has not yet been developed, a further effort is required to make this objective feasible (3), (4), (5).

Platelet aggregate has been widely used to accelerate tissue regeneration and repair in medical field. Notably, PRF mixed with bone substitute or PRF alone has so far been used as a graft material for sinus augmentation. CGF-CD34+ matrice is well known to accelerate new bone formation. (12), (13)

In our case report, we used the autogenous tooth graft combined with CGF- CD 34+matrice in the piezosurgical lateral approach.

CASE REPORT

An Albanian male, aged 30 Y.O.

Healthy conditions, no previous or current diseases.

Reference: Single-tooth implant placement, tooth Nr.16 extracted one year before Informed Consent– Verbal and written.

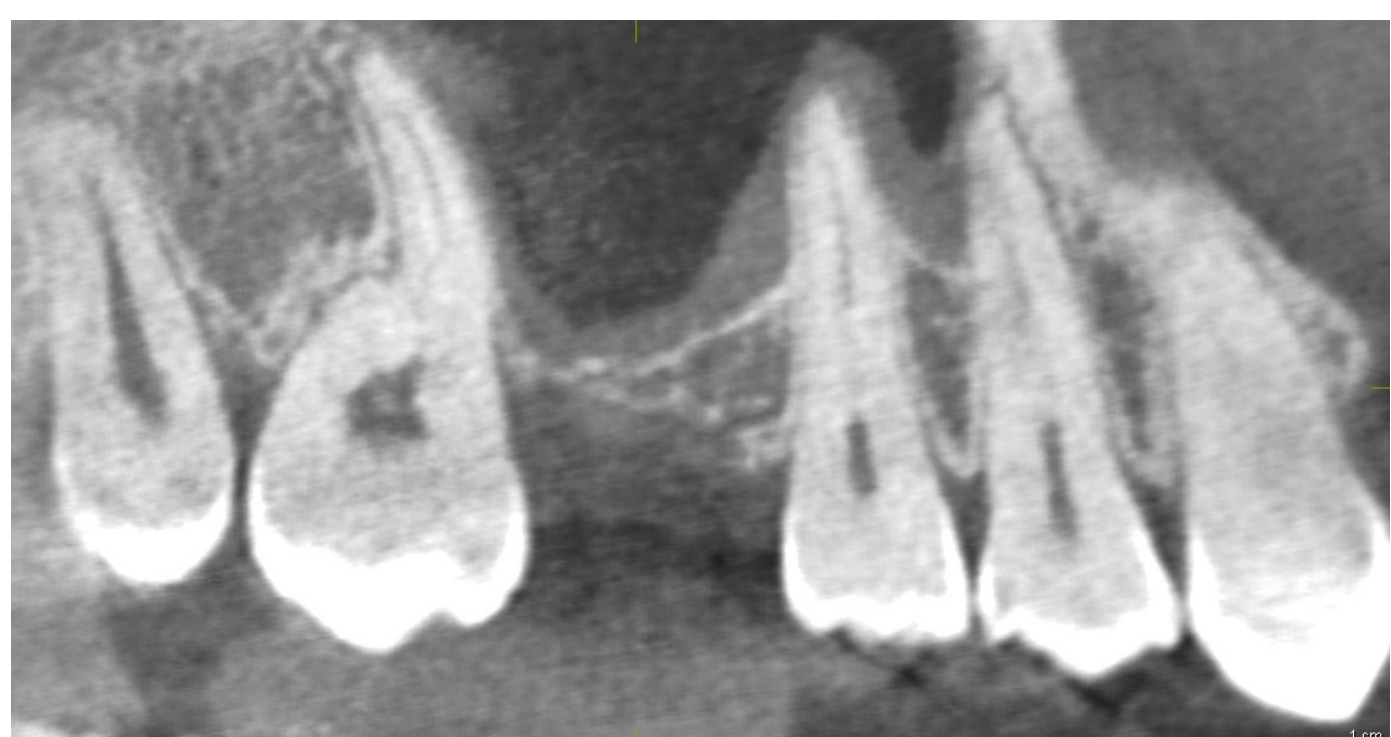


Figure 1. Preoperative CBCT/ panoramic image.

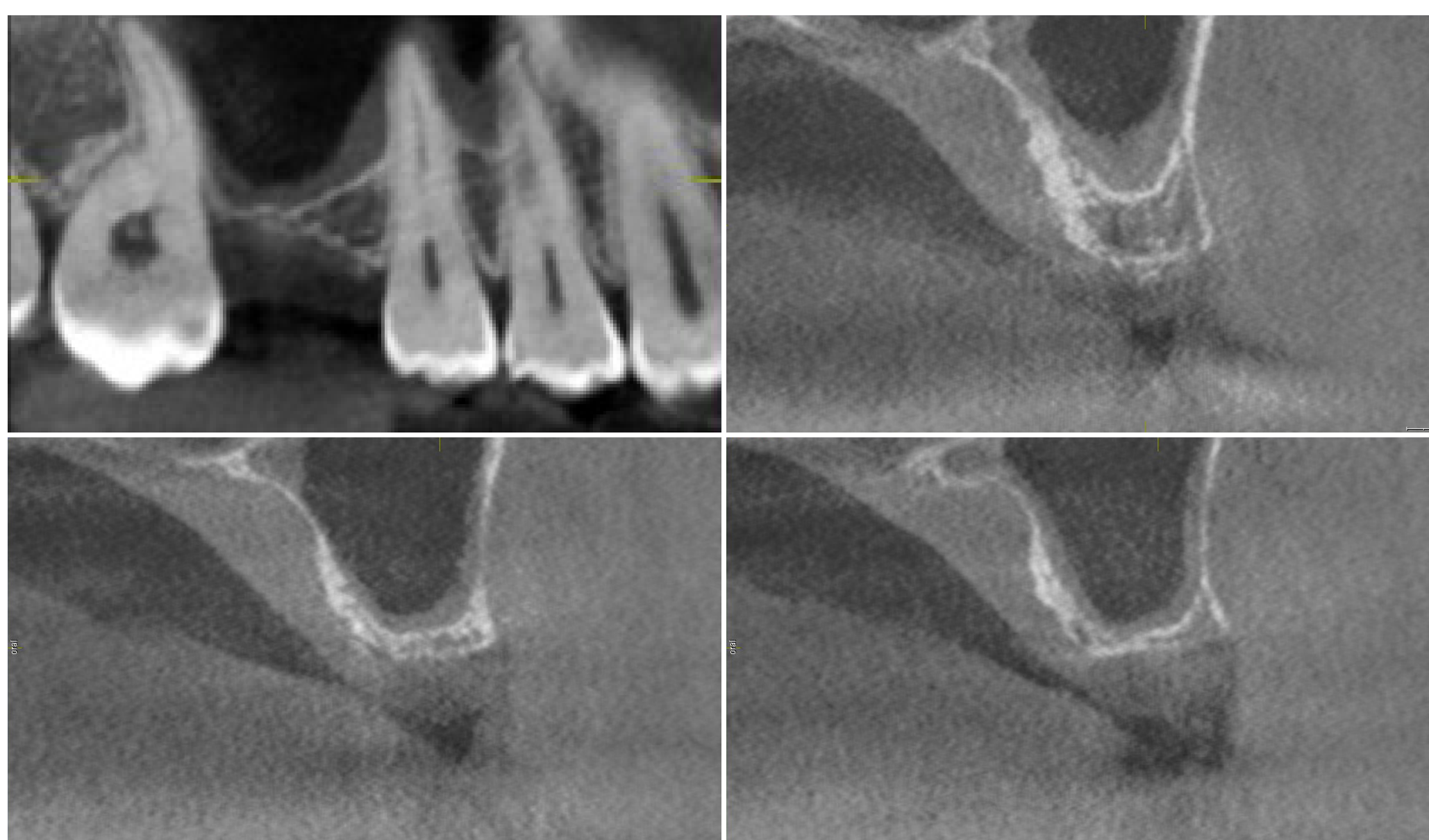

Figure 2. Defficient alveolar ridge, Cawood and Howell s.class.type VI.

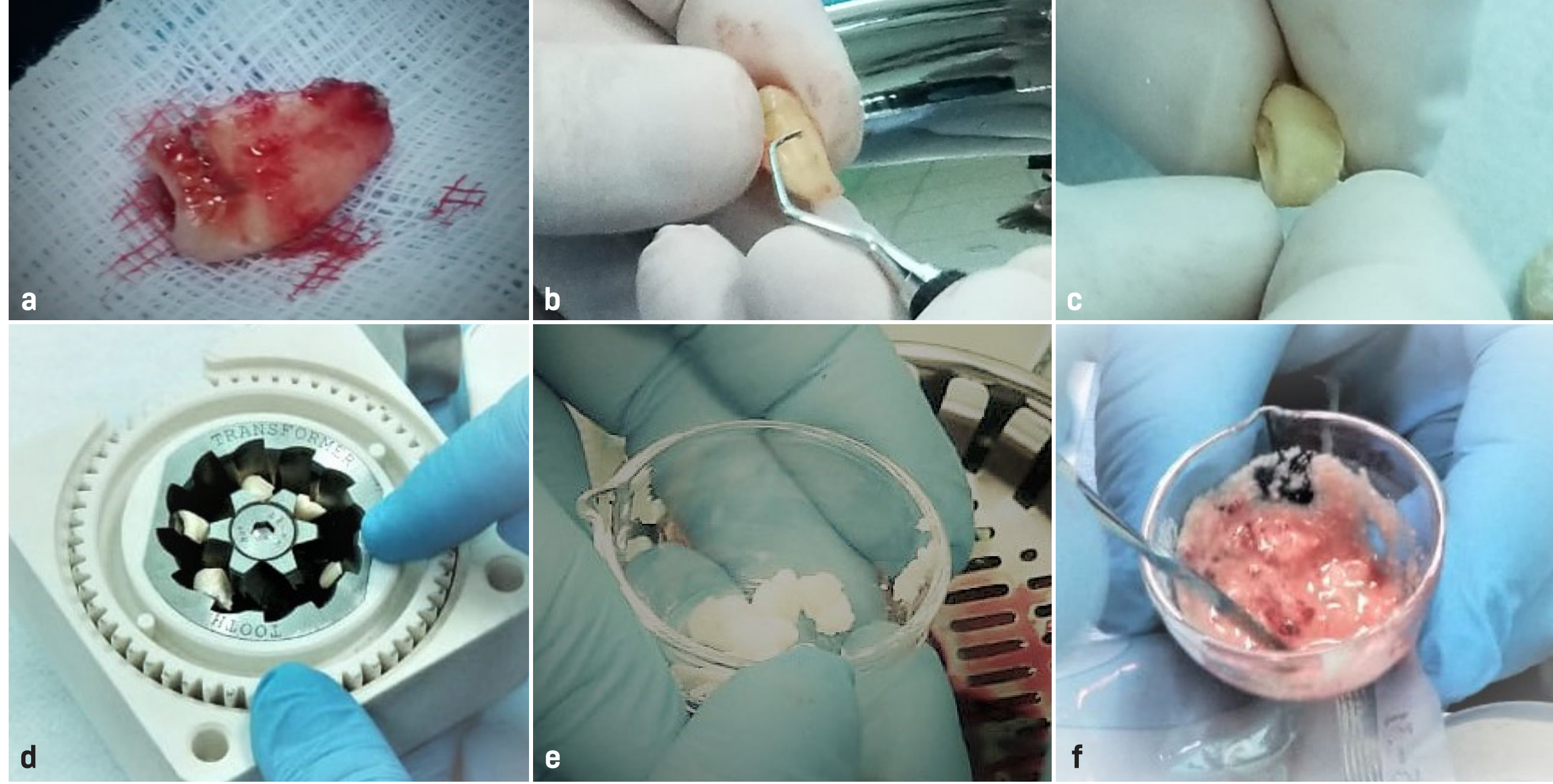


Figure 3. Extraction of tooth nr 18 (a), fabrication into auto bone graft powder (b), pieces of CGF mixed with autobone graft powder.

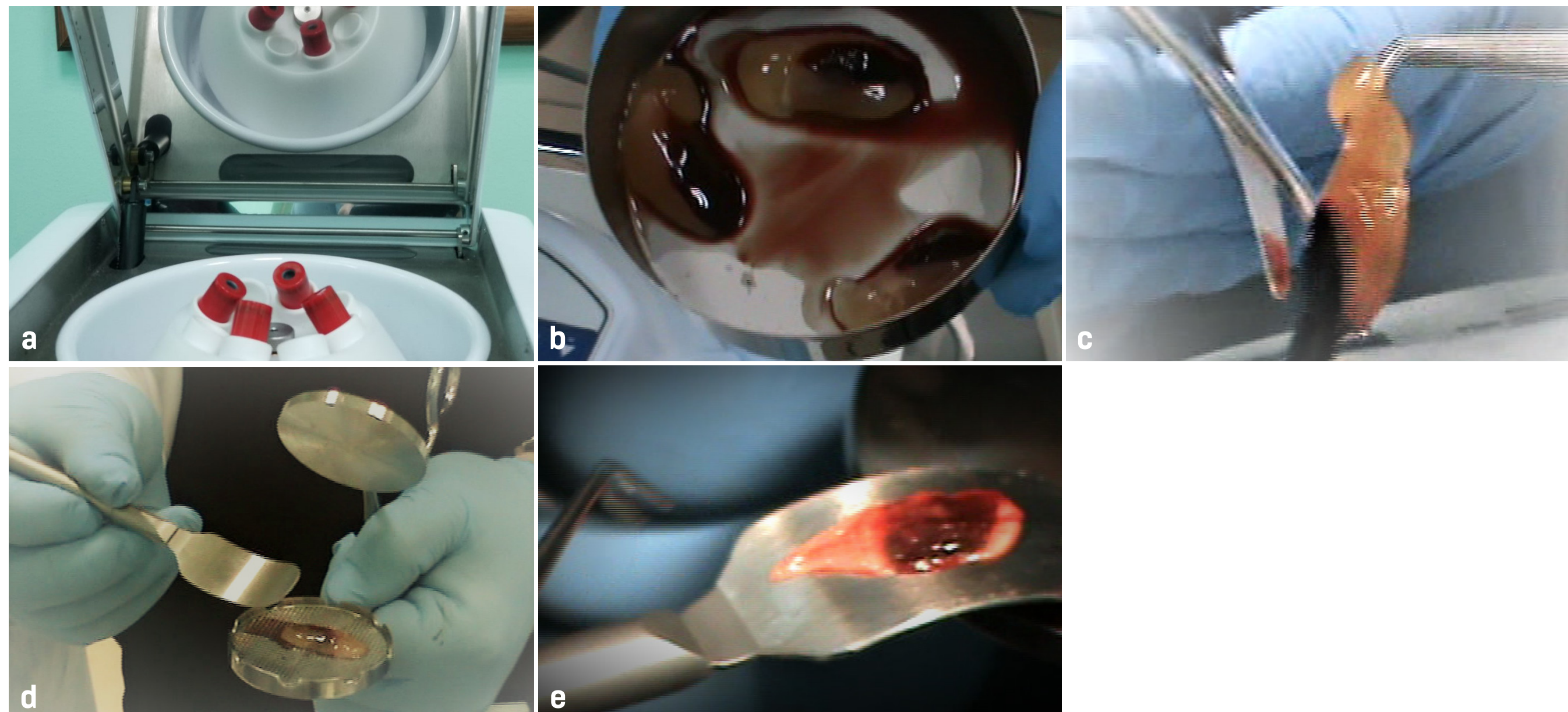


Figure 4. CGF -CD 34+ matrices (fibrine), (a-b) and production of a CGF biological membrane, (c-d) B– CGF –CD 34+matrices, yellow part –growth factors, red part –stem cells.

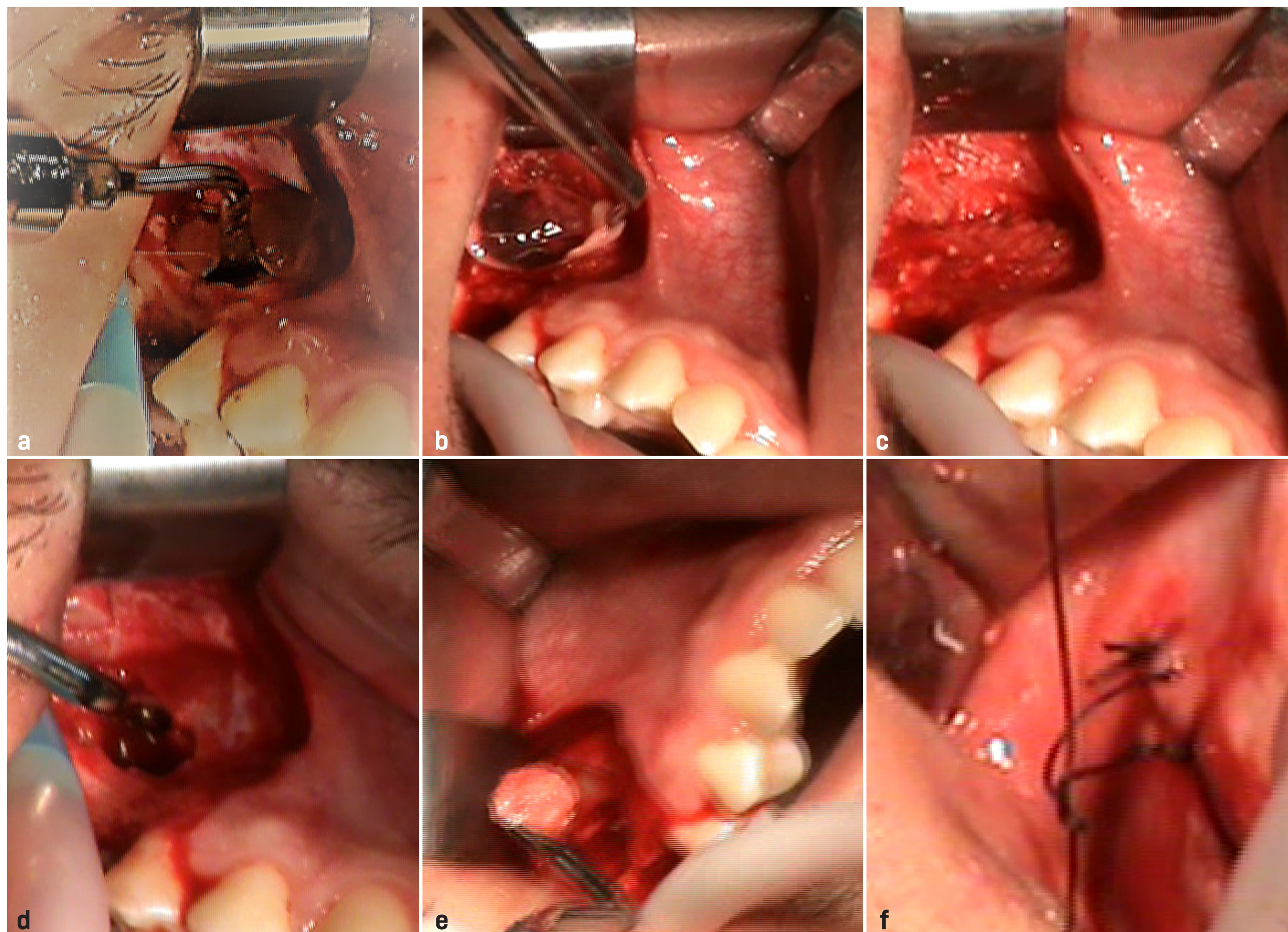


Figure 5. Surgical technique, (a) lateral window with usage of piezotome tip, surgery bone, (b) elevation of sinus membrane, (c & d) placement of auto bone graft powder mixed with CGF, (e) placement of CGF—CD34 + biological membrane, (f) suturing phase.

REFERENCES

1. S.TitsinidesAG, AgrogiannisBT, Karatzasc, Bone grafting materials in dentoalveolar reconstruction: A comprehensive review, Japanese Dental Science Review, Volume 55, Issue 1, November 2019, Pages 26-32
2. P. Kumar, B. Vinitha, G. Fathima, Bone grafts in dentistry, J Pharm Bioallied Sci, 5 (June (5) (Suppl. 1)) (2013), pp. S125-S127
3. Elio Minetti1, Marco Berardini2, *, Paolo Trisi2, A New Tooth Processing Apparatus Allowing to Obtain Dentin Grafts for Bone Augmentation: The Tooth Transformer, Identifiers and Pagination: Year: 2019, Volume: 13, First Page: 6, Last Page: 14, Publisher Id: TODENTJ-13-6, DOI: 10.2174/1874210601913010006
4. Nina Bono, Paolo Tarsini, Dr. Gabriele Candiani Demineralized Dentin and Enamel Matrices as Suitable Substrates for Bone Regeneration, First Published July 20, 2017 Research Article <https://doi.org/10.5301/jab-fm.5000373>
5. Young-Kyun Kim1,3, Junho Lee2, *, Ji-Young Yun1, Pil-Young Yun1, In-Woong Um4, Comparison of autogenous tooth bone graft and synthetic bone graft materials used for bone resorption around implants after crestal approach sinus lifting: a retrospective study, J Periodontal Implant Sci 2014;44:216-221, <http://dx.doi.org/10.5051/jpis.2014.44.5.216>
6. Kim, Young-Kyun & Um, In-Woong & Murata, Masaru. (2014). Tooth Bank System for Bone Regeneration - Safety Report -. Journal of Hard Tissue Biology. 23. 371-376. 10.2485/jhtb.23.371
7. K. Niranjani, Jaiganesh ramamurthy. Piezosurgery and its Clinical Applications in Periodontics Journal of Pharmaceutical Research & Clinical Practice, Jan-March 2014; 4(1):84-88
8. ManopKhanipouaDutmaneeSeriwatanachaiBKitanantBoonsrisethcSuphachaiSuphangulVerasakPairuchvejEratchapin LaovanitchSrisatjalukfNatthametWongsirichatg Bone graft material derived from extracted tooth: A review literature, Journal of Oral and Maxillofacial Surgery, Medicine, and Pathology, Volume 31, Issue 1, January 2019, Pages 1-7, <https://doi.org/10.1016/j.ajoms.2018.07.004>
9. K. Retna Kumar, K. Genmorgan, S. M. Abdul Rahman, M. Alagavel Rajan, T. Arul Kumar,1 and V. Srinivas Prasad2 Role of plasma-rich fibrin in oral surgery, J Pharm Bioallied Sci. 2016 Oct; 8(Suppl 1): S36–S38. doi: 10.4103/0975-7406.191963
10. Ioannis P.Georgakopoulos, Panayiotis Georgakopoulos, Textbook of CGF in Advanced Dentistry and Implantology, www.wagrosd.com
11. L.F. Rodella, G. Favero, R. Boninsegna, Growth factors, CD34 positive cells, and fibrin network analysis in concentrated growth factors fraction Microsc. Res. Tech., 74 (8) (2011), pp. 772-777, 10.1002/jemt.20968 Epub 2011/07/23
12. Eduardo Borie, Daniel García Olivé, Iara Augusta Orsi, Katia Garlet, Benjamin Weber, Víctor Beltrán, Ramón Fuentes, Platelet –rich fibrin application in dentistry :a literature review, Int J Clin Exp Med. 2015; 8(5): 7922–7929. Published online 2015 May 15.
13. Georgakopoulos I, Tsantis S, Georgakopoulos P, Korfiatis P, Fanti E, Martelli M, Costaridou L, Petsas T, Panayiotakis G, Martelli FS. The impact of Platelet Rich Plasma (PRP) in osseointegration of oral implants in dental panoramic radiography: texture based evaluation, Clin Cases Miner Bone Metab. 2014 Jan-Apr;11(1):59-66. Epub 2014 Jun 11. PubMed PMID: 25002881; PubMed Central PMCID: PMC4064443.

RESULTS

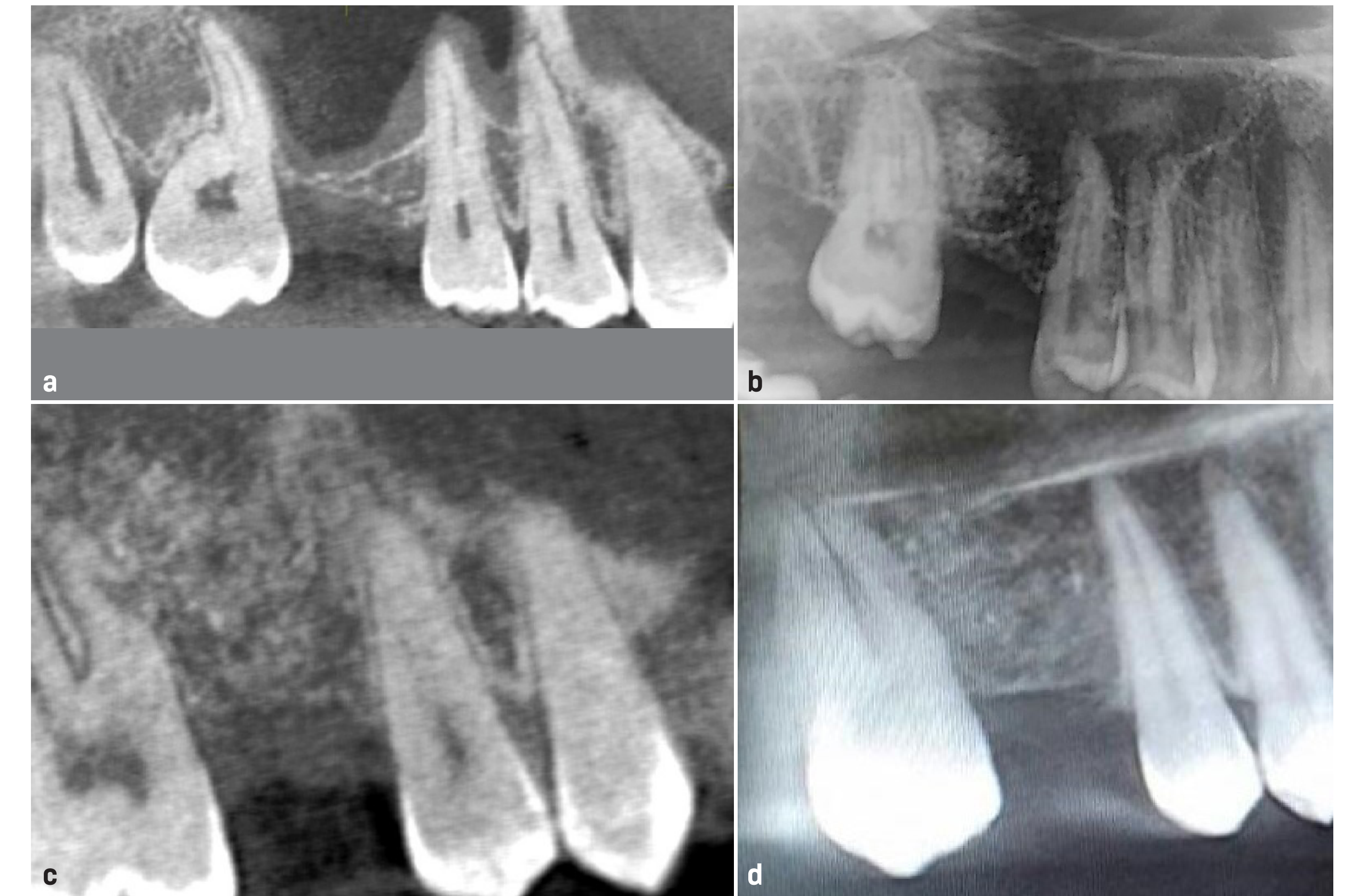

Figure 6. CBCT panoramic image before (a) and after 2 months (b) and 4 months (c), (d) 5 months.

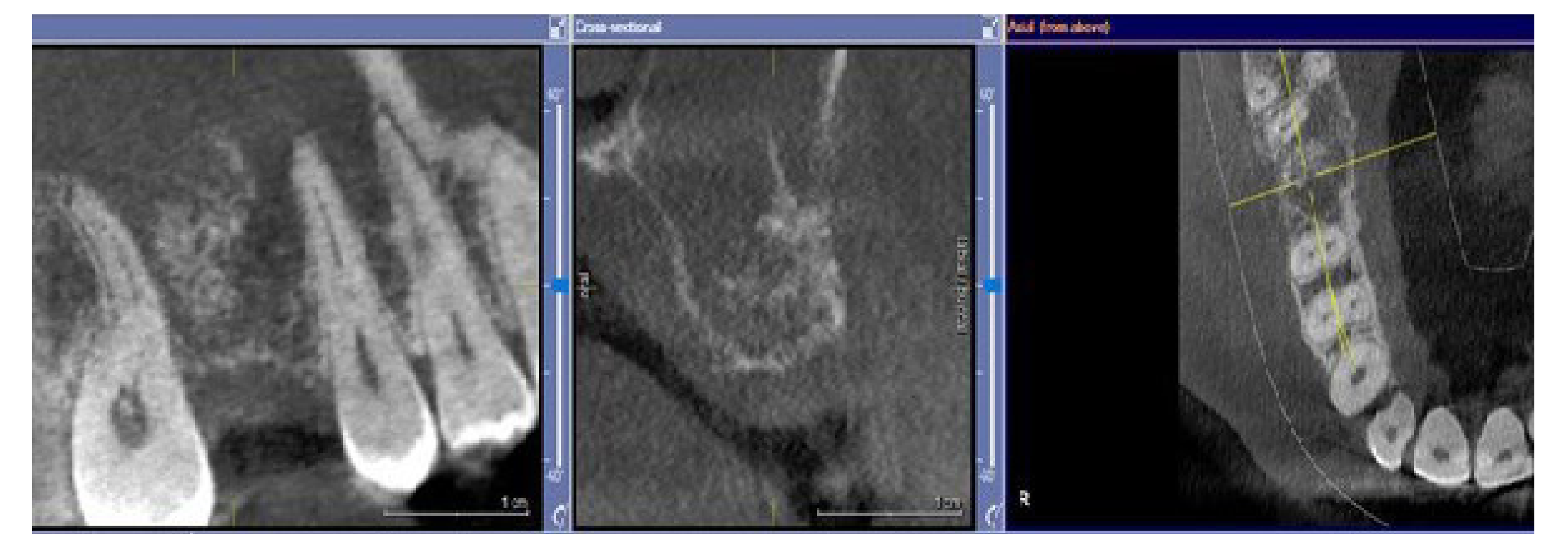


Figure 7. CBCT images, start of new bone formation after 2 months.

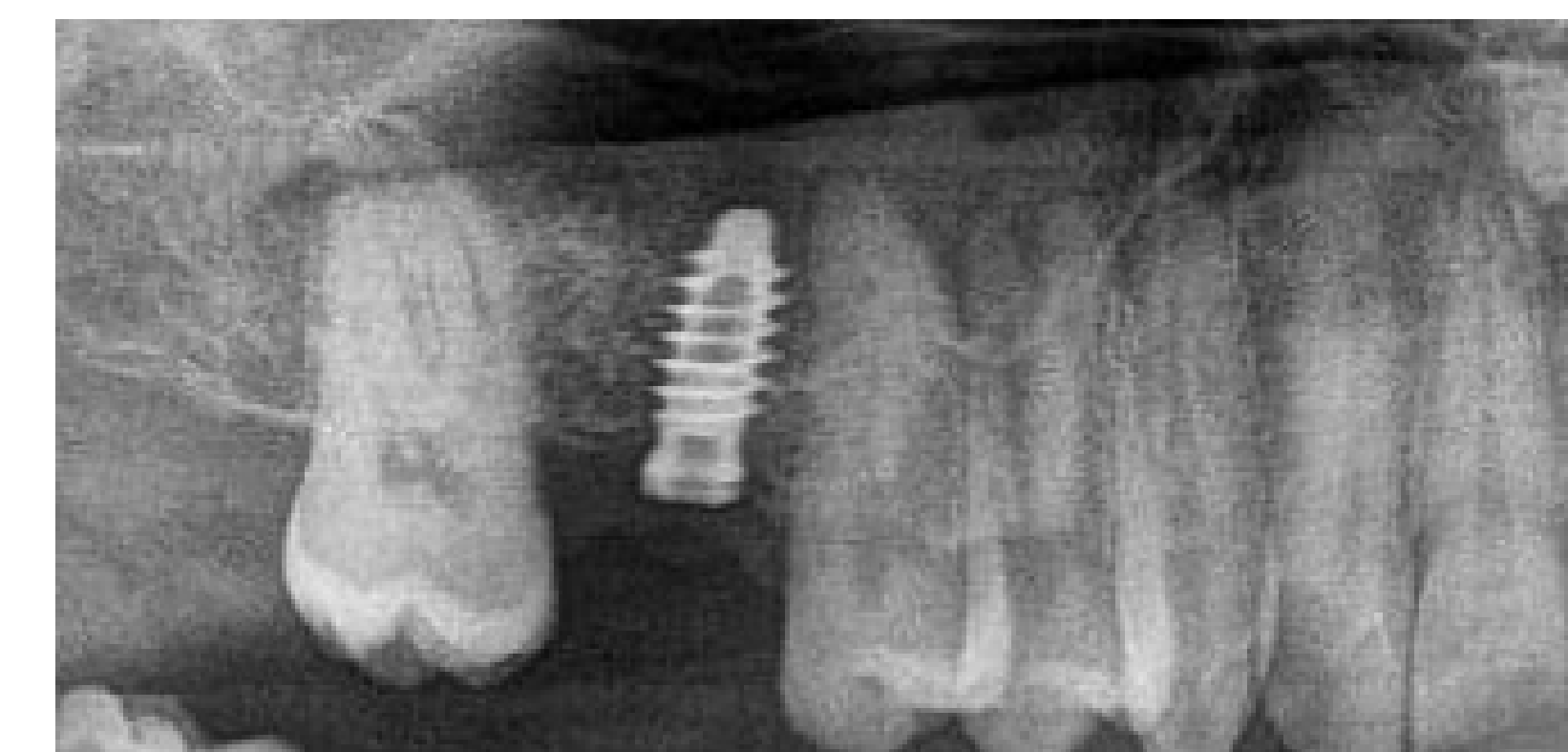


Figure 8. Implant placement after 5 months.

DISCUSSION AND CONCLUSIONS

When the residual bone height of less than 4 mm during the initial diagnosis, two-phase implant placement through sinus lifting via the lateral approach is recommended. (5) The traditional lateral approach using the surgical burs for antrostomy, implies a great risk of perforation of the schneiderian membrane.(7) We used the piezoelectric technique as a safer approach to the maxillary sinus in order to maintain the integrity of the sinusal membrane.

In sinus augmentation, several bone grafts are used to achieve the new bone formation.(2). Autogenous bone graft is the gold standart in bone regeneration procedures. Tooth and bone exhibit similar biochemical composition hence it could be utilised as bone grafting material. Autologus tooth graft is an innovative biomaterial but future studies with long follow up period are needed in order to better evaluate the potential of demineralized dentin autografts.(2, 3)

Platelet-concentrate fibrin is an evolution of the fibrin glue, which is widely used in the oral surgery. CGF use results in fibrin rich matrices that are much larger, denser and richer in GF. This shows better regenerative capacity and higher versatility when using the fibrin rich matrix. Studies show the CD 34+positive cells in CGF. They participate in remodeling and repair of the vasculature.(10, 11, 13)

In our case of sinus augmentation we used piezosurgical technique, tooth bone graft combined with CGF CD34+fibrine matrices. Outcomes of this procedure were: Safe and reliable approach to sinus membrane, no morbidity of the patient, our radiographic controls showed start of new bone formation after 2 months, continuous and significant bone remodeling over time becoming more and more homogeneous, improvement of the regenerative technique and low cost for the patient.